# Endemic Mycoses

**Endemic Mycoses** ..... 3
Introduction ..... 3
Epidemiology ..... 4
Classification ..... 5
***Subcutaneous mycoses*** ..... 7
***Chromomycosis*** ..... 8
Clinical presentation ..... 8
Pathogens ..... 8
Diagnosis ..... 10
Treatment ..... 10
***Mycetoma*** ..... 11
Pathogens ..... 14
Diagnosis ..... 14
Treatment ..... 14
***Sporotrichosis*** ..... 15
Etiology ..... 15
Clinical aspects ..... 15
Diagnosis ..... 17
Treatment ..... 18
***Rhino-entomophthoromycosis*** ..... 18
***Lobomycosis*** ..... 22
***Deep mycoses*** ..... 23
***Classic or American histoplasmosis*** ..... 24
Causative agent ..... 24
Clinical aspects ..... 25
Diagnosis ..... 27
***African histoplasmosis due to H. capsulatum var. duboisii*** ..... 28
Histoplasmosis treatment ..... 28
***Talaromyces marneffei (Previously known as Penicillium marneffei)*** ..... 28
Causative agent ..... 28
Clinical aspects ..... 30
Diagnosis ..... 30
Treatment ..... 31
***Coccidioidomycosis*** ..... 31
Causative agent ..... 31
Clinical aspects ..... 31
Diagnosis ..... 31
Treatment ..... 32
***Paracoccidioidomycosis*** ..... 32
***Blastomycosis*** ..... 34

# Endemic Mycoses

## Introduction

Medical mycology deals with the nature and the causes of the diseases occasioned directly (mycoses and allergies) or indirectly (poisoning) by fungi. Mycotoxins are toxic molecules that are present in various moulds. Reference is made to mycetism when a mycotoxin causes poisoning directly, as is the case for instance with *Amanita phalloides* (Death Cap). Mycotoxicoses are diseases caused by ingestion of foodstuffs in which toxins are released and therefore involves an indirect form of poisoning. The most well-known example is aflatoxicosis caused by aflatoxins produced by *Aspergillus flavus*. Some moulds can cause allergic syndromes such as extrinsic allergic alveolitis (e.g. cheese washer's lung, maltworker's lung). All these conditions differ from mycoses, which are a parasitic type of infection. This text deals only with mycoses.

Beware of the term "mycotic" and "mycosis", which can be misleading, as in "mycotic aneurysms" (in general due to bacteria, e.g. in endocarditis), mycosis fungoides (a neoplastic disease), and bothryomycosis (*Staphylococcus aureus* infection).

The majority of medical important fungi are land organisms in contrast to some more primitive fungi which have more in common with protista and exhibit a motile stage.

Fungi are eukaryotes. They differ fundamentally in terms of cell structure and organisation from bacteria (prokaryotes) and are not susceptible to most antibacterial antibiotics. They are heterotrophic, in other words they have to obtain their energy from already existing organic molecules. Consequently, many fungi live in association with living plants (often as harmful parasites, but also as beneficial symbionts, cfr mycorhiza) or as free saprophytes on dead organic substances. Like bacteria, they feed by absorption.

Two groups are distinguished among the microscopic fungi:

- **yeasts**, unicellular organisms that proliferate by budding and identification of which is based predominantly on morphological, as well as biochemical, properties such as oxidative assimilation or fermentation of various sugars.
- **moulds**, which are identified on the basis of morphological characteristics (filamentous).

An important term to understand is: Dimorphic fungi. These are fungi that can exist in the form of

both mould and yeast. This is usually brought about by change in temperature. An example is *Talaromyces marneffei*, a human pathogen that grows as a mold at room temperature and as a yeast at human body temperature.

## Epidemiology

In addition to their potential pathogenicity, fungi have one fundamental characteristic in common: they are first and foremost **saprophytes**. This means that their existence as a parasite in humans or animals is entirely unnecessary for the completion of their life cycle. They are at most **facultative pathogens,** which only parasitise if they encounter **promoting factors,** whether **systemic** or **local**. Examples of the former are deep candidiasis and aspergillosis in patients with neutropenia and superficial candidiasis and deep cryptococcosis in AIDS patients. Examples of local promoting factors are skin irritations, which predispose to cutaneous and subcutaneous mycoses.

The majority of the causative agents of mycoses are **exosaprophytes.** A patient only develops symptoms following exposure to the natural biotopes or ecological niches of the fungi. Knowledge of these possible sources of infection is therefore important.

Some moulds have a limited geographical distribution. An AIDS patient can catch an infection with the cosmopolitan *Cryptococcus* anywhere in the world but can only acquire an infection with *Talaromyces marneffei* (Previously Penicillium sp.) in Southeast Asia.

Other moulds live in or on humans.

*Candida albicans* the main causative agent of candidiasis, is an obligate **endosaprophyte.** The normal biotope of this yeast is the gastro-intestinal tract and the oral cavity in particular. Local or systemic **promoting factors** are responsible for the transition from the saprophytic to the parasitic phase.

*Malassezia furfur (Pityrosporum ovale)* is a **lipophilic** yeast present in everyone as an **episaprophyte** on the skin, which in certain circumstances can become pathogenic.

This may explain why with a few exceptions such as certain dermatophytoses and sporotrichosis, **mycoses** should **not** be considered **infectious**.

# Classification

## Superficial mycoses

- Tinea (synonym dermatophytoses): infections of skin, hair and nails. Tinea capitis, tinea barbae, tinea corporis, tinea cruris, tinea pedis, tinea unguium (onychomycosis). Examples of anthropophilic dermatophytes:
  - *Epidermophyton floccosum*
  - *Trichophyton mentagrophytes* var. *Interdigitale*
  - *Microsporum langeroni*
  - *Trichophyton rubrum*
  - *Trichophyton schonleini*

- Examples of zoophilic dermatophytes (which can also infect humans):
  - *Trichophyton verrucosum* – cattle
  - *Trichophyton equinum* – horse
  - *Microsporum canis* – cat (dog)
  - *Trichophyton mentagrophytes* var*. mentagrophytes* – rodent

- Malassezia furfur (*Pityrosporum ovale*): Pityriasis versicolor
- Superficial candidiosis: cutaneous, oral, genital. Causative agents: *C. albicans, C. glabrata*, *C. guilliermondii*, *C. krusei*, *C. parapsilosis*, *C. tropicalis*, etc.

## Subcutaneous mycoses

- Chromomycosis
  - *Fonsecaea pedrosoi*
  - *Fonsecaea compacta*
  - *Cladosporium carionii*
  - *Phialophora verrucosa*
- Mycetoma
  - Eumycetoma
  - Actinomycetoma (not due to fungi)

Examples of mycetoma:

**Red discharge**

- *Actinomadura pelletieri*

**White** or **Yellow discharge**

- *Acremonium strictum*
- *Actinomadura madurae*
- *Aspergillus nidulans*
- *Noetestudina rosatii*
- *Phaeoacremonium krajdeni*
- *Pseudallescheria boydii*

**Black discharge**

- *Aspergillus terreus*
- *Curvularia lunata*
- *Cladophialophora bantiana*
- *Exophiala jeanselmei*
- *Leptosphaeria senegalensis*
- *Leptosphaeria tompkinsii*
- *Madurella grisea*
- *Madurella mycetomatis*
- *Pyrenochaeta romeroi*
- Sporotrichosis
  - Sporotrix schenckii
- Rhino-entomophtormomycosis
  - *Conidiobolus*
  - *Basidiobolus*
- Lobomycosis
  - *Lacazia loboi*

## Deep mycoses

- **Cosmopolitan**
  - Aspergillosis : a few hundred species described. Most relevant examples:
    - *Aspregillus fumigates*
    - *Aspergillus flavus*

    - *Aspergillus niger*
  - Candidiosis, Causative agents: C. albicans, C. glabrata, C. guilliermondii, C. krusei, C. parapsilosis, C. tropicalis, C. kefyr, C. lusitaniae, C. zeylanoides etc.
  - Cryptococcosis
    - *Cryptococcus neoformans*
    - *Cryptococcus gatii*
    - *Cryptococcus albidus*
    - *Cryptococcus uniguttulatus*
  - Pneumocystosis
  - Mucormycosis
  - Phaehyphomycosis
- **Exotic (≠ tropic)**
  - Histoplasmosis
    - *Histoplasma capsulatum* var. *capsulatum*
    - *Histoplasma capsulatum* var. *duboisii*
  - Blastomycosis
  - Penicilliosis
    - *Talaromyces marneffei*
  - Emmonsiosis *(Emmonsia sp.)*
  - Coccidioidomycosis
    - *Coccidioides imitis*
  - Paracoccidioidomycosis
    - *Paracoccidioides brasiliensis*

LAST UPDATED BY ADMIN ON AUGUST 16TH, 2023

# Subcutaneous mycoses

## Introduction

The term subcutaneous mycosis means a disease in which the pathogen, an exosaprophyte, penetrates the dermis or even deeper during or after a skin trauma. The lesions gradually spread locally without dissemination to deep organs. However, most fungi which cause subcutaneous mycoses can also occasion deep mycoses in patients with severe underlying abnormalities (via the respiratory tract). Mycologically the pathogens of subcutaneous mycoses have only a few common

characteristics and belong to very different taxonomic groups.

Subcutaneous mycoses occur exclusively or predominantly in the tropics. This is related on the one hand to the geographical distribution of the pathogens and the ecological factors that determine their saprophytic growth and sporulation and on the other hand it is also the consequence of the medical underdevelopment in these regions. Imported or indigenous cases are only rarely found in Western Europe.

LAST UPDATED BY ADMIN ON JUNE 24TH, 2022

# Chromomycosis

## Clinical presentation

This chronic dermal/epidermal mycosis, also known as chromoblastomycosis is characterised by vegetative and verrucous lesions, which occur predominantly on the lower limbs. In addition erythematosquamous, nodular or ulcerating lesions are sometimes also found.

## Pathogens

The pathogens are dark-walled fungi (*Fonsecaea pedrosoi*, *Fonsecaea compacta*, *Cladosporium carrionii*, *Phialophora verrucosa* etc.), which are saprophytes on plants and wood.

© CD-ROM ILLUSTRATED LECTURE NOTES ON TROPICAL MEDICINE

Chromoblastomycosis. Copyright ITM

Chromoblastomycosis, syn. chromomycosis; hyperkeratotic lesions foot; Fonsacaea (Phialophora) infection, copyright ITM

## Diagnosis

Microscopic examination of crusts in KOH shows the presence of irregular, 10-20 µm large, brown-walled elements with transverse septa, 'sclerotic cells'. The specific causative agent can only be identified by culture.

## Treatment

1. Many clinicians find chromomycosis very resistant to antifungal treatment.
2. Surgery if possible (ideal for incipient lesions)
3. Heat therapy, as well as cryotherapy (for lesions with limited extend)

4. Itraconazole : 200-400 mg/day (+ ?5-fluorocytosine: 100-150 mg/kg/day)
5. Saperconazole  might be more effective than itraconazole
6. Terbinafine : 500 mg/day for 6-12 months, after 2-4 months a reduction of 70% of the sclerotic cells is seen, Cure: 40% after 4 months, 75% after 8 months, 83% after 12 months. Terbinafine might be the first choice treatment.
7. Japan: fluconazole  200 mg/day + heat therapy (improvement after 2 weeks!)
8. Some patients have responded favorable to treatment with amphotericin B
9. Dematiaceous fungi are very sensitive (in vitro) to the new triazoles voriconazole and posaconazole, but further clinical data are needed.
10. The place of the latest triazoles isavuconazole, ravuconazole and albaconazole is still unclear but if a parallel with their action against other fungal infections can be made, they might be promising.

LAST UPDATED BY ADMIN ON JULY 15TH, 2022

# Mycetoma

Mycetomas are chronic, inflammatory swellings with numerous sinuses, caused by moulds or bacteria. The causative agent can be seen in the bloody or non-bloody pus and sometimes with the naked eye in the form of granules. In 75% of cases, a mycetoma is localised on the foot (Madura foot). In addition to involvement of soft tissue; bone tissue is severely affected with osteolysis on the one hand and hyperostosis on the other.

Madura foot patient in King Saud Medical Complex. Riyadh. Saudia arabia
(Image source: Haitham Alfalah, Halfalah)

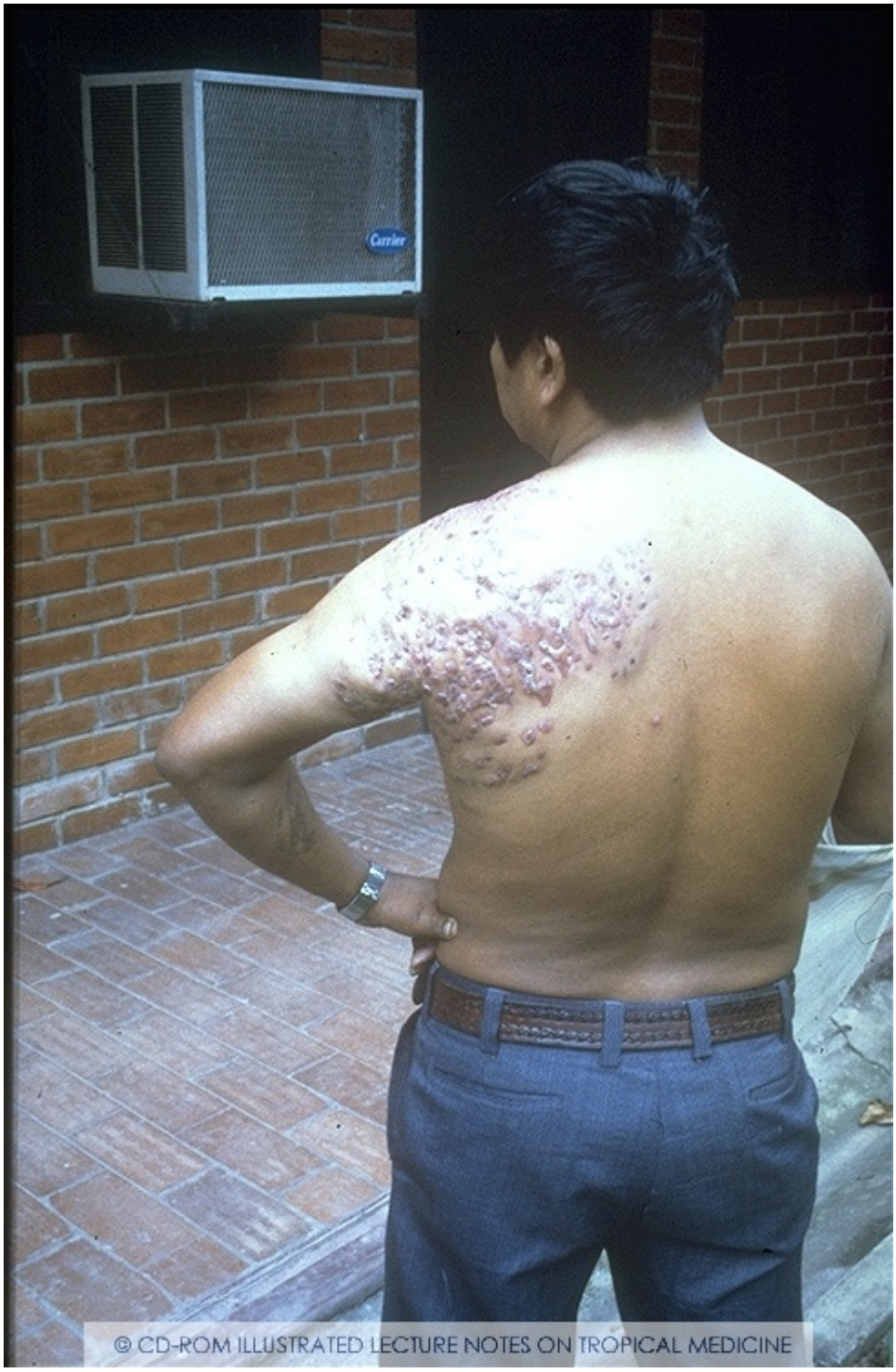


Mycetoma of shoulder and back

## Pathogens

Mycetomas are caused by 2 totally different groups of organisms: the first are moulds and the second are filamentous bacteria in the order Actinomycetales. In the first case they are referred to as eumycetomas (mainly Africa), in the second as actinomycetomas (mainly Latin-America). Also in India, mycetoma is prevalent. The difference is very important for therapy. All causative agents of fungal mycetoma are exosaprophytes that have penetrated deep into the tissue with a splinter of wood or a thorn. The primary reservoir of the causative agents is believed to be the soil. The limited geographical distribution of most pathogens and their natural history explain why mycetomas occur practically exclusively in the tropics. Eumycetoma can be caused by more than 42 different fungal species.

## Diagnosis

The differential diagnosis between fungal and actinomycotic mycetomas is based on the examination of the granules and/or culture. The compact microcolonies of the causative agents differ from one another in terms of colour, shape, dimensions and composition. Black granules are always of fungal origin (e.g. *Madurella mycetomatis*); small red granules are specific for the actinomycotic *Streptomyces pelletieri*; whitish-yellow granules can be fungal or actinomycotic in nature.

In the direct examination of a crushed granule in KOH, the distinction between fungal and actinomycotic granules can be made on the basis of the presence or absence of true hyphal fragments.

Most information is obtained from the histological examination of a deep biopsy taken from around the path of a sinus. Vesicular or filamentous elements are seen in fungal granules (Gomori-Grocott stain). Only *Madurella mycetomatis* the most common causative agent of eumycetoma, can be detected histologically by the presence of a brown cement. With the other moulds identification should be made by culture.

New DNA-isolation techniques on fungal cultures (takes 6 weeks) or directly on the grains (immediate result) are under development. Serological tests exist but don’t detect all different species and are not used in routine diagnosis.

## Treatment

Until recently only surgical removal of the whole affected area was successful in treating eumycetoma. Itraconazole for 12 months (or longer) in combination with removal of the mass, is the

current the treatment of fungal mycetomas, but only results in 37% cure rate. The newer azole derivates posaconazole, voriconazole, isavuconazole and ravuconazole have excellent in-vitro activity. Their real life efficacy is under review and isolated case studies have shown resolution of symptoms with these agents. For actinomycetoma, the first choice treatment is combination treatment of 2 drugs, such as streptomycin or amikacin IV with dapsone or cotrimoxazole for a long duration (depending mainly of the causative pathogen). New data suggest that co-amoxiclav (Augmentin™) acid can be used instead of aminoglycosides to reduce ototoxicity and kidney toxicity.

LAST UPDATED BY ADMIN ON JULY 15TH, 2022

# Sporotrichosis

## Etiology

Sporotrichosis is only caused by the mould, *Sporothrix schenckii*. It is an exosaprophyte on plants, wood and in the soil (peat moss). *S. schenckii* is a dimorphic mould. At 37°C and on rich nutrient media the yeast phase is obtained with oblong yeast cells.

## Clinical aspects

© CD-ROM ILLUSTRATED LECTURE NOTES ON TROPICAL MEDICINE

Sporotrichosis lesions with spread via the lymphatics. Copyright Alexander von Humboldt Institute, Peru

The classic presentation is the lymphocutaneous form. After an initial lesion, the inoculation chancre, subcutaneous nodules appear followed by ascending lymphangitis. The nodules progressively penetrate the skin and ulcerate. The most common localisations are the hand and the forearm. In addition to this typical lymphocutaneous form there is also one with disseminated skin lesions, a local cutaneous form, often on the face which according to some authors occurs in re-infections and extracutaneous sporotrichosis with involvement of the mucous membranes, bone, muscles, lungs or systemic infection. Pulmonary localisations without involvement of other organs occur in endemic areas (South America) probably more than is thought. This chronic pulmonary disease is often mistaken for smear-negative tuberculosis or chronic pulmonary aspergillosis.

**Differential diagnosis:**

1. Sporothrix schenckii
2. Blastomyces dermatitides
3. Coccidioides immitis
4. Cryptococcus neoformans
5. Histoplasma capsulatum
6. Mycobacterium marinum, M. chelonae, M. abscessus, M. kansasii
7. Nocardia brasiliensis and N. asteroides
8. Leishmania sp (mainly L. guyanensis).
9. Francisella tularensis
10. Staphylococcus aureus
11. Streptococcus pyogenes
12. Bacillus anthracis
13. Burkholderia pseudomallei (melioidosis)

## Diagnosis

In contrast to all other mycoses, the diagnosis of sporotrichosis is based not on the detection of the pathogen by direct or histological examination, but solely on culture. It involves collecting a small quantity of the milky pus from ulcerated lesions after the removal of the superficial crusts and then inoculating it onto a Sabouraud nutrient medium. Growth is obtained after a few days of incubation at 25°C and the typical asexual spore formation is easily identified.

## Treatment

For cutaneous forms, oral potassium iodide (saturated solution 1g/ml) can be used. As an alternative, terbinafine 2 x 250 mg/day for maximum 32 weeks can be used. Cure can be expected after 8 weeks. Local heat therapy (I.R. or compresses) is sometimes used. The killing rate of the fungal cells is markedly higher at 40°C than at 37°C. Itraconazole and terbinafine can be used of for small lesions, as well as for systemic cases. Amphotericine B (liposomal formulation is preferred) is preferred for severe cases. Posaconazole (Noxafil) has good in vitro activity against *S. schenkii*, but more clinical data are needed. Fluconazole (Diflucan), voriconazole (Vfend) and ravuconazole are ineffective in sporotrichosis.

LAST UPDATED BY ADMIN ON JULY 15TH, 2022

# Rhino-entomophthoromycosis

© CD-ROM ILLUSTRATED LECTURE NOTES ON TROPICAL MEDICINE

Rhinoentomophtoromycosis; nasofacial phycomycosis; Coniodobolus coronatus (Entomophtora coronata), copyright ITM

Rhinoentomophtoromycosis; nasofacial phycomycosis; Coniodobolus coronatus (Entomophtora coronata), copyright ITM

© CD-ROM ILLUSTRATED LECTURE NOTES ON TROPICAL MEDICINE

Rhinoentomophtoromycosis; subcutaneous phycomycosis; Coniodobolus coronatus (Entomophtora coronata), copyright ITM

Zygomycosis is a term referring to infections with zygomycetes, and more specifically infections such as mucormycosis and entomophthoromycosis (synonyms of the latter are the tongue-twisting and jaw-breaking “rhino-entomophthoromycosis” and “rhino-entomophthoramycosis”). Rhino-entomophthoromycosis is a slowly progressing tropical infection of the subcutaneous tissue or paranasal sinuses caused by *Conidiobolus coronatus* or related species. Severe mutilations with grotesque deformation of the face can ensue. Basidiobolomycosis is often considered together with rhino-entomophthoromycosis. *Basidiobolus ranarum* affects subcutaneous tissue in areas such as buttocks, thighs and arms. Localisation in the face results in severe facial swelling, with gross deformity of eyelids and cheeks. The differential diagnosis includes Burkitt’s lymphoma. Lymphatic filariasis usually presents in a different manner.

Histopathology will show fungal elements, granulomata and eosinophils. Culture will confirm the diagnosis. Azoles such as itraconazole or the allylamines terbinafine – with or without surgery – should be tried as treatment, although there is insufficient clinical experience. Amphotericin B is an option for *Basidiobolus* infections.

LAST UPDATED BY ADMIN ON JULY 15TH, 2022

# Lobomycosis

Lobomycosis is a very rare infection. It is a self-limited chronic fungal infection of the skin endemic in rural regions in South America and Central America. The prevalence of the disease is high among the Caiabi Indians of Brazil and among the Amoruas tribe of the Casanare state in Colombia. It was the Brazilian physician Jorge Lobo who in 1931 in Recife first described this infection. He gave the name keloidal blastomycosis. The condition was called Lobo disease in 1938, and in 1958 the name lobomycosis was applied.

The organism responsible for lobomycosis has yet to be cultured in vitro. The causative organism is a blastomycosis *Lacazia loboi*, formerly named *Loboa loboi.* The natural reservoir of the pathogen is unknown. Its likely habitat is somewhere in the rural environment because the disease occurs in humans living in rural areas. Soil and vegetation seem to be likely sources of infection. Since the pathogen has been recovered from lobomycotic lesions of *Tursiops truncatus* (“bottlenose dolphins”)

in Florida and in the Bay of Biscay in Europe, an aquatic reservoir seems likely. A case of dolphin-to-human transmission has been documented in 1983 in a dolphin handler. As for clinical symptoms the name keloidal blastomycosis describes the lesions very well. Lobomycosis often develops at sites of minor trauma but sometimes no history of trauma can be recalled. The disease predominately affects exposed areas and extremities. Skin lesions slowly develop over time. Only after the lesions have become large do patients tend to consult a doctor. The lesions often begin as small papules or pustules, mildly pruritic or resulting in a burning sensation. The disease leads to verrucous or lobulated keloidal nodules and crusty plaques. Lesions are well defined, smooth and painless. They are easily moved around since they lie free over the deeper tissues. Older lesions typically become wart-like and ulcerative with satellite lesions resulting from autoinoculation. The mucosae are spared. The disease does not seem to heal spontaneously. The infection may spread proximally from the extremities suggesting lymphatic dissemination. Patients lack other systemic symptoms and lobomycosis does not affect the general health of the patient although squamous cell carcinoma has been described on old scar lesions. Keloids are the most important differential diagnosis and are much more common.

Diagnosis relies on a skin biopsy. The fungus is abundant in lobomycotic skin lesions. It is a spherical intracellular yeast 6-12 µm in diameter. The melanin-containing birefringent 1 µm thick cell wall resists digestion by macrophages. Linear or radiating chains of 5-10, even 20 organisms linked by tubules are characteristic. The organism can be seen with haematoxylin and eosin but the best stain is Grocott silver-methenamine which will show the typical yeasts chains. Attempts at medical treatment have failed. Surgery is successful only when the lesion is small and can be fully resected. Repeated cryotherapy appears to be more successful. The present antifungals do not seem promising, but more study is needed. Cases of successful treatment with posaconazole have been described. Clofazimine and dapsone have been tried with limited success.

LAST UPDATED BY ADMIN ON JUNE 24TH, 2022

# Deep mycoses

## Introduction

Deep or systemic mycoses can be subdivided into

- Cosmopolitan deep mycoses, such as aspergillosis, candidosis and cryptococcosis. They are caused

by fungi that occur worldwide.
- Exotic deep mycoses, including coccidioidomycosis and histoplasmosis and infection with *Penicillium marneffei*, the pathogens of which have a limited geographical distribution.

### Exotic deep mycoses

The exosaprophytic moulds that cause exotic deep mycoses have the lungs as their portal of entry. They are dimorphic, i.e. they occur in two forms. In the environment they are filamentous, while in vivo they exhibit another morphology that of yeasts. These moulds are capable of causing disease in patients without predisposing factors. The severity of the condition varies according to the inoculum and the patient's immune status. In patients without predisposing factors dissemination is rare and associated with a very large inoculum. In at risk patients (AIDS) dissemination always occurs even if only a small number of spores are inhaled. Dissemination leads to the secondary form in which numerous deep foci are possible and cutaneous lesions are also often observed.

The laboratory diagnosis is based on the specific morphology which the pathogen exhibits in vivo and on the culture of the saprophytic phase. Manipulation of the cultures is dangerous! There are reliable serological tests which are of diagnostic and prognostic value. For therapy as an alternative to amphotericin B use is increasingly, and successfully, being made of the azoles (itraconazole), particularly for the secondary chronic forms or relapse prevention (cfr. cryptococcosis).

LAST UPDATED BY ADMIN ON JUNE 24TH, 2022

# Classic or American histoplasmosis

Histoplasmosis is also known as "**Cave disease**", "**Darling's disease**", "**Ohio valley disease**", "**reticuloendotheliosis**," **'spelunker's lung**" or "**caver's disease**". This mycosis occurs primarily in the southeast of the USA, but is not exclusively North American. Native cases also occur in South America, Africa and Asia. Apart from a handful of Romanian and Italian cases those found in Europe have been imported.

## Causative agent

The causative agent *Histoplasma capsulatum* var. *capsulatum*, is an exosaprophytic mould that is isolated in the USA from various biotopes such as chicken manure, soil under starling roosts, seagull breeding sites and bat guano in caves (cave disease or speleologist's disease).

The filamentous phase is found in the environment or in culture at 25°C characterised by round spores with a thick wall, surrounded by protrusions (chlamydospores) and small round spores with a smooth wall. In vivo, in the parasitic phase; small, ovoid yeasts of 3-4 µm are found in the cells of the RES (histiocytes, monocytes).

## Clinical aspects

'The syphilis of the fungus world', meaning that histoplasmosis is one of the "Great Imitators". Histoplasmosis has been described as an illustration of the large variety of clinical forms.

In most cases, after contact with a low dose, an asymptomatic infection (99%) is seen or a self-limiting flu syndrome occurs (1%).

At high inoculum or with temporary suppression of immunity an acute pulmonary disease can occur. After recovery calcifications in the lung and lymph nodes are seen in 1/3 of cases after 1-2 years.

A chronic mild form is described in adults in the event of a temporary suppression of cellular immunity. This involves an endogenous re-activation, as in ex-colonial soldiers, 10-20 years after they have returned from Africa, South America or Asia, or a re-infection in people still living in endemic areas. Oropharyngeal and nasal lesions and lesions of the vocal chords closely resembling malignant cells (nodules, ulcerations) and which may be associated with dysphagia and dysphonia are seen. In 50% of cases the adrenal glands are also involved. Systemic histoplasmosis is described in AIDS patients, sometimes with very severe cutaneous and mucosal lesions, as well as a possible cerebral involvement (meningitis). It results in a systemic granulomatous disease with preferential lesions on lips and in the adrenals.

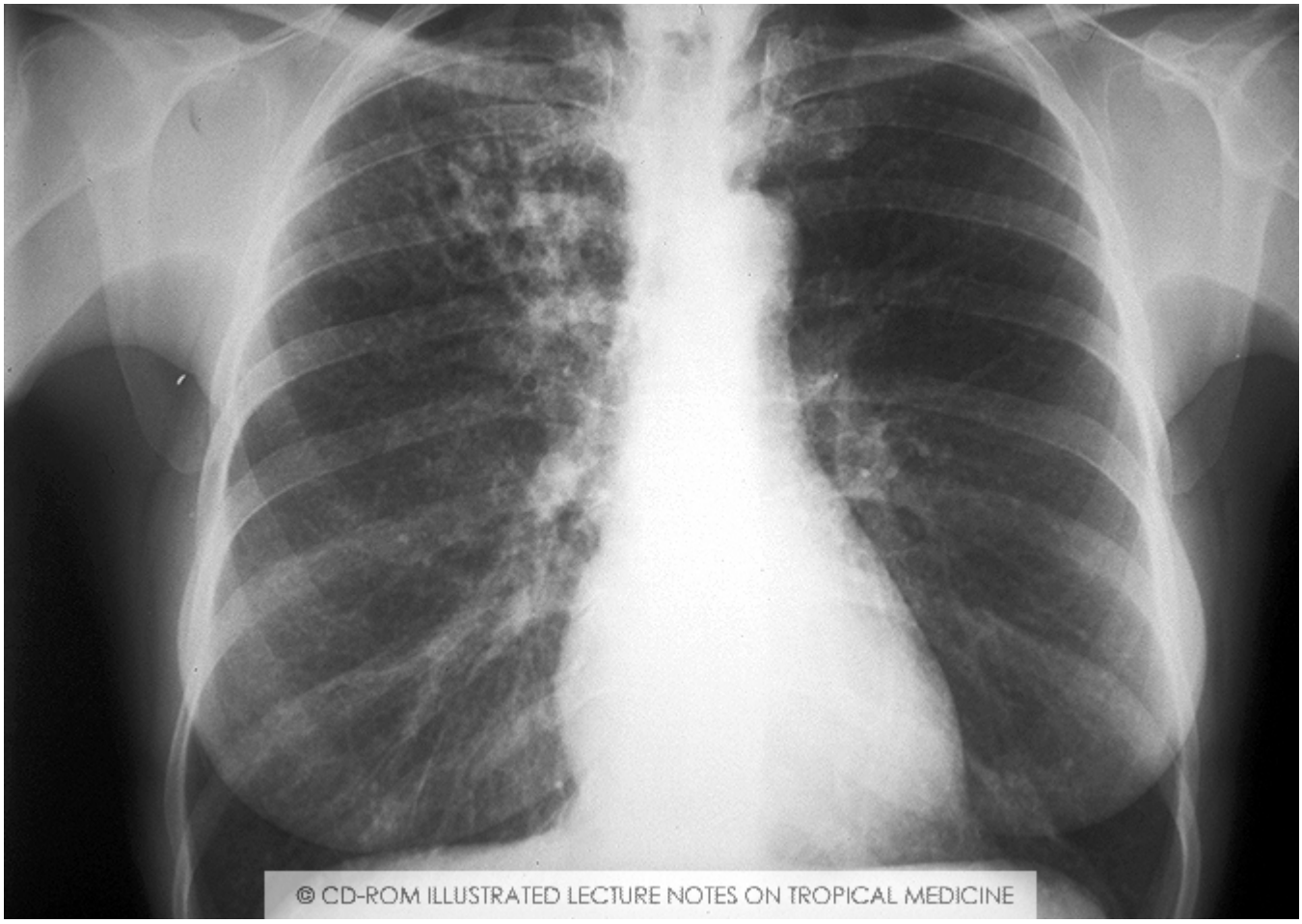


Chest X-ray, pulmonary histoplasmosis. Copyright ITM

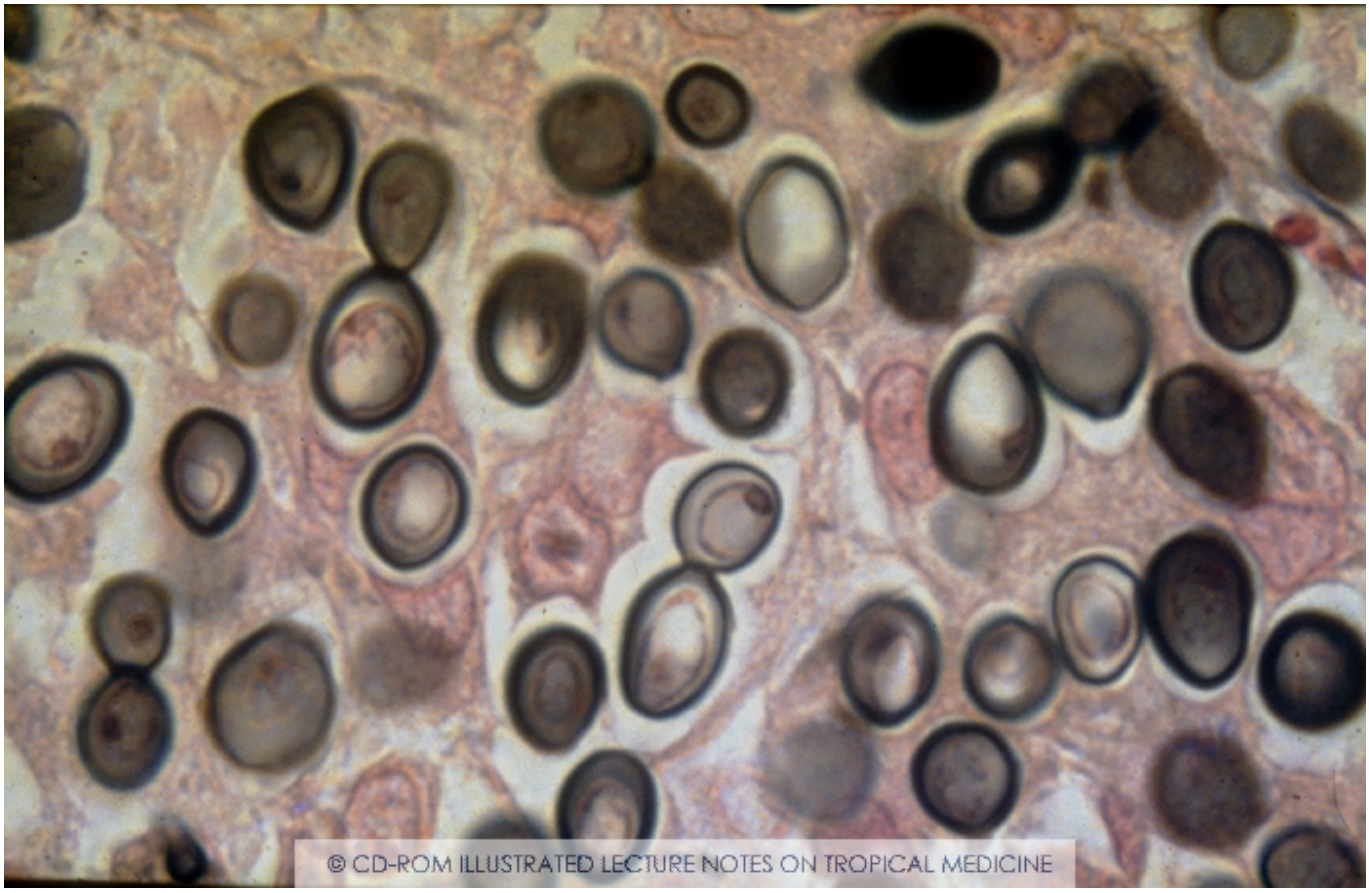


Histoplasma duboisii, histoplasmosis. Microscopic smear. With special thanks to Mr De Vroey. Copyright ITM

## Diagnosis

The diagnosis of histoplasmosis is made by direct examination of the parasitic phase (yeast) in sputum, bone marrow or blood. *Histoplasma* can also be found in histological preparations in RES cells. The intradermal reaction with histoplasmin is of no diagnostic value. The serological tests (immunodiffusion and complement fixation) are based on the detection of specific antibodies or on the detection of specific antigens (RIA). Both variants of *H. capsulatum* are level 3 pathogens and should only be cultured in a laboratory with the appropriate security procedures.

LAST UPDATED BY ADMIN ON JULY 15TH, 2022

# African histoplasmosis due to H. capsulatum var. duboisii

African histoplasmosis is geographically confined to Central Africa. Although it is established that the pathogen is also an exosaprophytic mould, the natural biotope remains unknown**.**

In the parasitic phase, *H. capsulatum var. duboisii* exhibits large, round spores of 10-15 µm. In the saprophytic phase, the two varieties are morphologically indistinguishable.

Patients with this chronic mycosis always exhibit polymorphous cutaneous lesions, bone and lymph node involvement and ultimately random deep localisations. When the disease follows an acute course (e.g. in AIDS patients), the yeast cells remain small and the infection is usually ascribed mistakenly to the variety *capsulatum*. In experimental infections also, cells exceeding the variety *capsulatum* in size are found only after a long time.

## Histoplasmosis treatment

In the majority of immunocompetent individuals, histoplasmosis resolves without any treatment. Antifungal medications are used to treat severe cases of acute histoplasmosis and all cases of chronic and disseminated disease. Typical treatment of severe disease first involves treatment with amphotericin B, followed by oral itraconazole. Alternatives to itraconazole are posaconazole, voriconazole, and fluconazole.

LAST UPDATED BY ADMIN ON JUNE 24TH, 2022

# Talaromyces marneffei (Previously known as Penicillium marneffei)

This mycosis only occurs in Southeast Asia and is usually associated with suppression of cellular immunity. The pathogen *T. marneffei* was first isolated from bamboo rats in Vietnam and has since been found in patients with a disseminated often fatal mycosis. The disease is an AIDS indicator.

## Causative agent

*Talaromyces marneffei* is a dimorphic mould. When it was classified as a *Penicillium* species it was

regarded as the only species that can cause invasive disease, in contrast to other *Penicillium* species which are normally understood to be unimportant in human disease. In the saprophytic phase it produces a red pigment that diffuses in agar. In the parasitic phase, intrahistiocytic and intramacrophagic elements are found which divide by fission and not by bud formation.

Infection with Talaromyces marneffei in an AIDS patient. Remark the typical umbilicated papular skin lesions

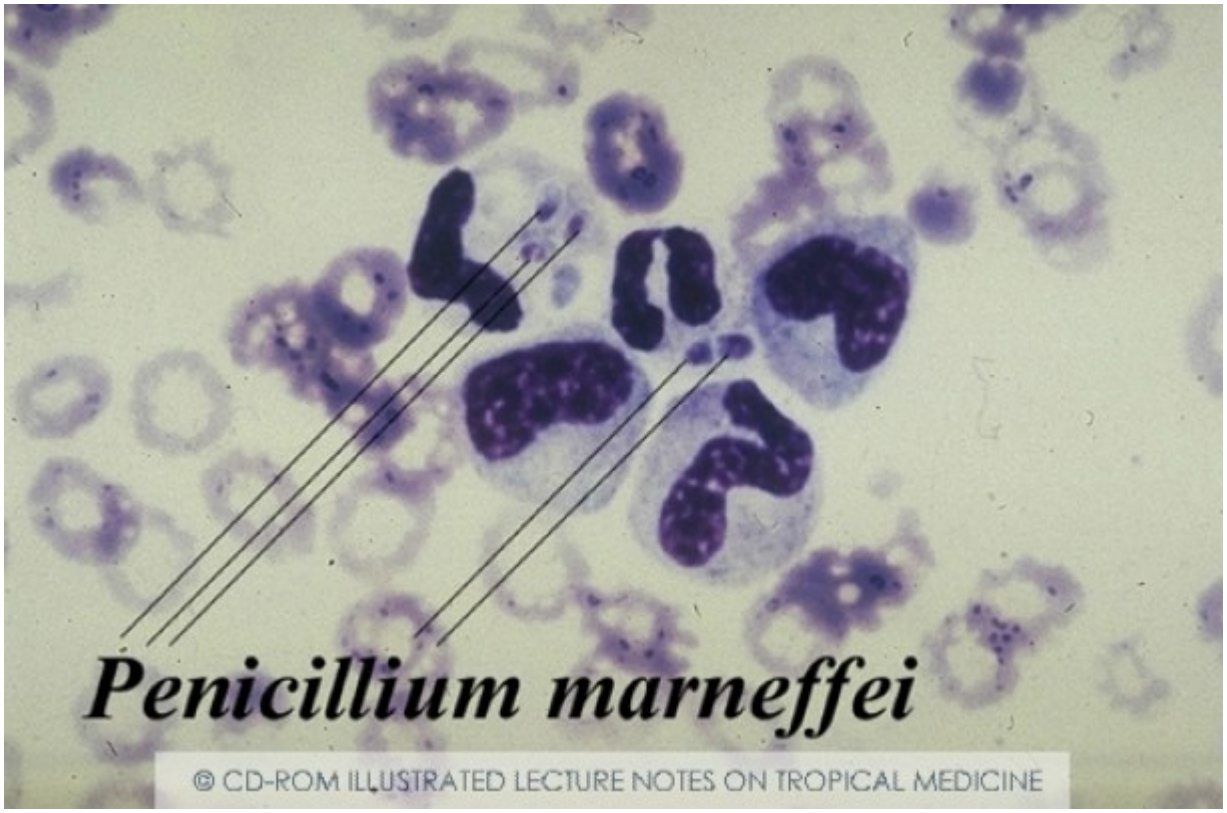


Microscopy of thin bloodsmear of an AIDS patient from Southeast Asia. Talaromyces marneffei. Copyright ITM

## Clinical aspects

The portal of entry is the lung and the infection spreads rapidly or otherwise via the RES. In AIDS patients, fever, marked weight loss, hepatosplenomegaly and often also cutaneous lesions are seen. DD with cryptococcosis, histoplasmosis. This infection is now increasingly recognized as a disease in sold organ transplant recipients who travel.

## Diagnosis

The diagnosis of this mycosis is based on direct examination of sputum, BAL, bone marrow and material from skin lesions or on histological examination where the intrahistiocytic elements can be observed. *T. marneffei* can be cultured but the manipulation should be performed in a level 2 laboratory. Reliable serological tests are being developed.

## Treatment

In severe disease treatment with amphotericin B IV or voriconazole IV should be started, followed by itraconazole or voriconazole po. Secondary prophylaxis with itra- or voriconazole is suggested when the CD4-count is below 100 cells/mm³ in HIV-patients on HAART.

LAST UPDATED BY ADMIN ON JULY 15TH, 2022

# Coccidioidomycosis

The disease is endemic in the wilderness areas of the southwest of the United States. In addition, foci have been described in Central and South America. Despite the pathogenicity of all *Coccidioides immitis* strains, it is estimated that only 0.2% of cases showed symptoms of deep localisations and/or skin granulomas in the period before 1990. Since then the number of cases has steadily increased not only because of the AIDS epidemic, but also as a result of earthquakes and sandstorms (disturbance of soil structure).

## Causative agent

*Coccidioides immitis* is a dimorphic mould found in its filamentous phase in soil. The pathogenic spores are easily dispersed from dry ground or material. In vivo (parasitic phase) no yeasts are found, but instead spherules, large, spherical elements of 20-80 µm diameter. These spherules contain numerous endospores.

## Clinical aspects

60% of those infected exhibit no symptoms or only minor respiratory disorders. These people are coccidioidin-positive. Approximately 40% go on to develop lower respiratory tract infections after 1-3 weeks, sometimes with erythema nodosum or erythema multiforme. The fungus can be spontaneously eliminated but it is preferable to administer azoles. About 5% of patients retain cavities and nodules in their lungs. Exceptionally in people with a normal immune system -but in 100% of AIDS patients- an extrapulmonary form is found with meningitis and bone involvement.

## Diagnosis

Spherules are found on direct or histological examination. The culture is relatively atypical and should only be performed in a level 3 laboratory. The coccidioidin skin test can be used for people who suffer

a primary infection but anergy (absence of response) is possible in progressive disease. Spherulin is supposedly more sensitive. No cross-reactions have been described. There are other serological tests (latex agglutination, immunodiffusion, complement fixation, ELISA) for the detection of antibodies. PCR demonstrated high sensitivity.

## Treatment

Many infections in healthy patients do not require treatment. Only severe infections or infections in immunosuppressed people needs treatment with itra-, keto- or fluconazole for 3 to 6 months.

LAST UPDATED BY ADMIN ON JUNE 24TH, 2022

# Paracoccidioidomycosis

South American blastomycosis or paracoccidioidomycosis, ulcers lips. Paracoccidioides brasiliensis. Photo Cochabamba

Paracoccidioidomycosis is caused by infection with Paracoccidioides brasiliensis. The yeasts have a typical steering wheel aspect caused by budding. Copyright ITM

Paracoccidioidomycosis or South American blastomycosis occurs in discrete foci in Latin America. It is thought that the fungus (*Paracoccidioides brasiliensis*) exists in the soil as a mold, with infections happening through the inhalation of conidia (spores). These spores convert into yeasts in the lungs and are then thought to spread to other sites haematogeneously and via the lymphatics. Most primary infections are self-limiting. The organism has the ability to remain dormant in the human host for long periods. It can cause clinical disease at a later time if host defense would become impaired (e.g. depression of cell mediated immune responses). Overt infection results in a progressive mycosis with lesions of the skin, mucous membranes (especially mouth, lips and nose) and internal organs. Long asymptomatic periods enable patients to travel far from endemic areas before developing clinical problems. Lesions in the face, naso- and oropharynx resemble espundia (mucocutaneous leishmaniasis), lupus vulgaris (skin tuberculosis) and syphilis. Papules will ulcerate and enlarge both peripherally and deeper into the subcutaneous tissue. A hard hyperkeratotic border may surround a deep ulcerating crater on the skin. Extensive coalescent ulcerations may eventually result in the

destruction of the uvula, epiglottis and vocal cords. Eating and drinking become difficult and painful. Lymphatic infections lead to painless enlargement of cervical, supraclavicular and/or axillary nodes. Draining sinuses may form. Visceral lesions in liver, spleen and lymph nodes can lead to abdominal pain, hepatosplenomegaly and low-grade fever. Pulmonary involvement occasionally leads to mild symptoms, including cough and sputum production, although the radiograph of the chest can show dramatic involvement of the lungs. Infections tend to be very chronic, but not fatal. Diagnosis relies on demonstration of the yeasts in tissue/secretions. The yeasts are usually abundantly present in the bases and edges of slowly expanding ulcer. In tissue specimens, the yeasts are rather large (15 µm) with multiple buds, thereby resembling the steering wheel of a boat. Gomori staining of biopsies is useful. Serology by immunodiffusion is positive in ± 98% of cases. Azoles such as itraconazole are usually very effective as treatment. Amphotericin B can be used if there is no success with oral itraconazole or in case of severe infection. Sulfonamides can be used, but have only moderate activity and should be administered for very long periods.

LAST UPDATED BY ADMIN ON JULY 15TH, 2022

# Blastomycosis

Blastomycosis -also known as North American blastomycosis or Gilchrist's disease- occurs in a geographically limited area of the south central and midwestern USA, upstate New York and southern Canada. A few cases have been described from Africa, the Middle East, India and Mexico. The fungus occurs in soil enriched with animal excreta and moist, acid, decaying organic material. Infection follows the inhalation of conidia (asexual spores) of *Blastomyces dermatitidis*. Both man and dogs can be infected. The spores will convert into yeasts, which will invade the lungs and occasionally spread haematogeneously to several organs, especially skin, bone or urogenital system. Pulmonary infection can be asymptomatic. Genital involvement such as chronic epididymitis, mimicking tuberculosis. Cough, low to moderate fever, dyspnoea and chest pain, purulent/bloody sputum, pleural fluid, weight loss and prostration occur in symptomatic patients. Radiological studies usually reveal pulmonary infiltrates and enlarged hilar lymph nodes. Progressive pulmonary blastomycosis resembles tuberculosis or a neoplasm. Raised single or multiple verrucous cutaneous lesions that tend to have an abrupt downward sloping red-purplish border are usually present in disseminated blastomycosis. The border extends slowly, leaving a central atrophic scar. Those skin lesions can resemble skin cancer. Bones such as ribs and vertebrae are frequently affected (25-75%). Lesions appear both destructive and proliferative on radiography. Central nervous system lesions are uncommon. Acute self-limiting blastomycosis is rarely diagnosed. The organism is found in clinical specimens as a thick, double-walled cell, 5-20 µm in diameter, sometimes even reaching 30 µm. Some yeast cells have a

single bud. Definite identification is via culture but detection of the above mentioned yeast cells in pus, sputum or urine is very suggestive. Gomori's methenamine silver stain and PAS staining are useful for biopsies. Serology is not useful. Untreated disseminated blastomycosis is usually progressive and can be fatal. Itraconazole (200-400 mg/day) is used as a first-choice treatment. If no improvement occurs the dose of itraconazole can be increased to 800mg per day or switch over to IV amphotericin B. Follow-up in order to identify a relapse should continue for several years.

LAST UPDATED BY ADMIN ON JUNE 24TH, 2022